# REVIEW ARTICLE

## Role of 3D/4D Sonography in Obstetrics and Gynaecology

**Mukesh Mittal*, Pankaj Nitharwal****

**ABSTRACT**

Modern 3D/4D sonography provides a routine single plane image as in 2D ultrasound as well as complete sets of volume data in the computer memory. After complete acquisition of all sets of volume, all data can be accessed from the memory and we can detect normal and abnormal findings in both obstetrics and gynecology in different display modes. Furthermore, we can perform examination of digital storage of volumes which permits virtual examinations by reloading of volumes and navigating them in the absence of the patient.

This review article will give insight of recent advances in technology of 3D/4D ultrasound in obstetrics and gynecology.

**INTRODUCTION**

First ultrasound machine (Combison 330) for medical imaging was launched by Kretztechnik AG, Austria in 1989. Initially many gynecologists were dubious about the clinical use of 3D/4D technique of sonography. Later on 3D/4D ultrasound found worldwide acceptance after 1997, when the First World Congress for 3D Sonography in Obstetrics and Gynecology held in Mainz, Germany[1].

The American Institute of Ultrasound in Medicine held a consensus conference in 2005, where 3D ultrasound was established an imaging tool for a huge number of obstetrical and gynecological conditions. However, 3D/4D technology is not only useful for prenatal diagnosis but also for gynecological ultrasound and breast ultrasound as well[2].

**Technical aspects**

Generally, 3D ultrasound examination consists of four main steps: data acquisition, 3D visualization, volume/ image processing, and storing of volumes, rendered images or image/volume sequences.[3] Steps for acquisition of 3D/4D image by transvaginal/transabdominal sonography-

1. Data acquisition

a) Orientation in the 2D image

b) Definition of the region of interest (ROI)

c) Volume acquisition

2. 3D/4D visualization

a) Multiplanar display

b) Tomographic display

c) Surface-rendered image (surface mode, light mode, HD live mode)

d) Transparent display (maximum mode, X-ray mode)

e) Glass body display (combination of surface or transparent rendering and color Doppler)

f) Animated display (rendering of image sequences)

3. Volume/image processing

a) Electronic scalpel

b) Filtering

c) Contrast and brightness control

d) Color selection

4. Storage of volumes or rendered images or volume sequences

Volume rendered image storage - With the advent of newer technology 3D/4D intracavity transducer (5-9 MHz) are used for volume acquisition in gynecology and early pregnancy. 3D/4D abdominal probes (4-8 MHz) are necessary in later pregnancy and in large or highly located gynecologic tumors. A different 3D/4D transducer (6 to 12 MHz) is required for the breast examination.

Currently several display modes can be used to demonstrate the ROI in 3D and 4D (Table 1). This allows the operator to choose always the most appropriate mode for the visualization of normal or abnormal findings in obstetrics and gynecology.

**Table 1: Overview on 3D/4D visualization modes**

| 3D | 4D |
|---|---|
| Multiplanar mode | Multiplanar mode |
| Multislice/TUI mode | Multislice/TUI mode |
| 3D surface mode | 3D surface mode |
| Transparent mode | Transparent mode |
| Glass body mode | Glass body mode |
| Inversion mode | Inversion mode |
| VCI mode | VCI mode |
| Omni View mode | Omni View mode |
| 3D-animation (cine) mode | STIC mode |
| HD live mode | HD live mode |

*Professor, **Assistant Professor,
Department of Radiodiagnosis, SMS Medical College, Jaipur.
**Corresponding author:**
Dr Pankaj Nitharwal, Assistant Professor, Department of Radiodiagnosis, SMS Medical College, Jaipur.
Email: pankaj6468@gmail.com
Mobile: +91-8447445938

With the latest development, known as the HD live technique, a step toward even more realistic visualization of the fetus can be achieved. HD live uses a movable virtual light source that can illuminate the examination object from all sides[3]. The reflection and scattering behavior of the structures in relation to the light direction is used for calculation of the brightness and shadow of the fetal surface.

The human skin-based color spectrum and the movable virtual light source allow almost photographic imaging of fetuses. 3D/4D technique can be used to detect with greater details and clarity of normal anatomical structures and congenital anomalies in early and late pregnancy (limb deformities, facial anomalies, and facial expression) (Fig 1 A & B). The virtual light source provides extraordinarily realistic imaging of fetuses like actual photographs[3].

**Application of 3d/4d sonography in obstetrics**

3D and 4D ultrasound play an important role in early demonstration of normal and abnormal findings in the first, second and third trimester. The various display options give opportunity to operator to choose that display mode which gives the best overview of the ROI. Adequate amniotic fluid pocket is required for the 3D/4D surface rendering of the structures being imaged[4]. With the help of the glass body mode by a combination of gray scale 3D ultrasound and color power Doppler the fetal/ embryonic circulation can be demonstrated.

Figure: 1A- Gray scale 2 D image in radial ray syndrome shows radial deviation of hand,

Figure:1B - Surface view (HD live) of a fetus with radial ray syndrome shows radial deviation of hand.

With the interactive display of 3D images, the examiner can demonstrate all types of visible abnormalities in the most appropriate mode, showing the extent of the lesion in all dimensions. Triplanar demonstration of a true midsagittal section is required for the exact measurement of nuchal translucency (NT) in the first trimaster[5,6]. In the late trimesters the multiplanar display mode is helpful identifying a flat fetal profile or micrognathia or pathologic brain structures like partial or completely absent corpus callosum or ventriculomegaly[7-10]. Neural tube defects, abdominal defects, abnormalities of the gender and defects of the limbs including hands and feet can be diagnosed more precisely by surface rendered images. Abnormal ossification of fetal skeleton e.g. abnormalities of the skull, spine, chest, pelvic bones and the long limb bones can be diagnosed by the transparent mode[11,12]. Complex fetal cardiac anomalies can be diagnosed by 3D/4D fetal echocardiography using STIC technique (Fig- 2)[13].

**Application of 3d/4d sonography in gynecology**

The main advantage of transvaginal 3D/4D ultrasonography is the ability to generate transverse sections of the true pelvis in addition to conventional sagittal and coronal scans. Also, the examiner can scroll through a stored volume millimeter by millimeter in all three planes and can rotate the volume in all three directions[14]. It helps to locate the lesion in all three planes. The ability to display all three orthogonal planes simultaneously on the monitor enables a precise volumetric analysis. A direct live image of organs such as the uterus can be obtained by 3D render surface view or transparent view. Exact diagnosis of uterine anomalies can be done by rotating the stored image in an upright position to display the endometrium in the coronal plane[15] (Fig 3 A & B)

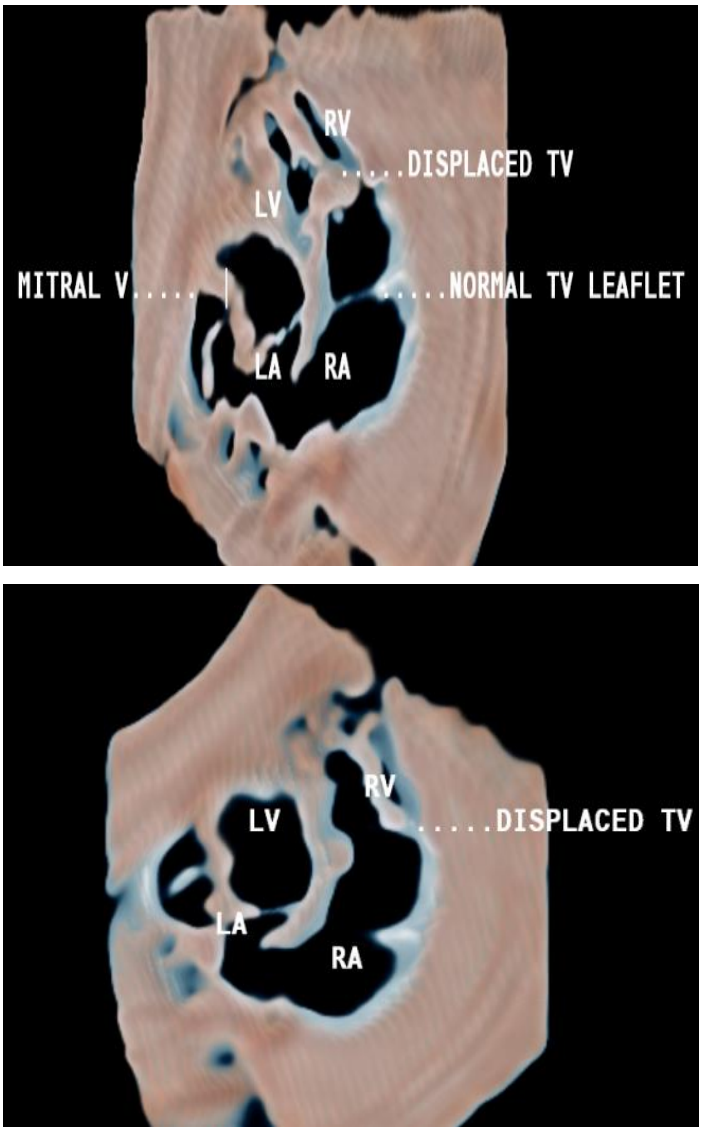


Figure: 2 STIC technology in a case of ebstein anomaly shows displaced tricuspid valve

3D sonography gives a clear picture of the inner and outer contour of the myometrium while even hystero-salpingography gives information about only the uterine cavity. Endometrial volumetry may be done in vitro fertilization therapy and in patients with suspected tumors. The exact coronal section makes it also possible to check precisely the position of an intrauterine device[16]. In the investigation of uterine tumors, fibroids can be accurately localized and their volume can be precisely determined. Glass-body rendering enables the operator to demonstrate uterine vascularity in three-dimensions. In particular neovascularization can be shown in endometrial and cervical cancer[17].

The ovaries can be depicted with the multiplanar and the surface mode. Both can be used to evaluate follicular maturation in spontaneous and stimulated cycles. The surface mode can be used to demonstrate cystic or solid tumors of the ovary and tumors of the fallopian tube. The glass body mode can provide impressive 3D views of the vascularity of benign tumors and neovascularity of borderline and malignant tumors of the ovary[17].

In infertility clinics, 3D ultrasound can be used to obtain sonographic views of the normal hystero-contrast sonography for the evaluation of the uterine cavity as well as fallopian tubes[17].

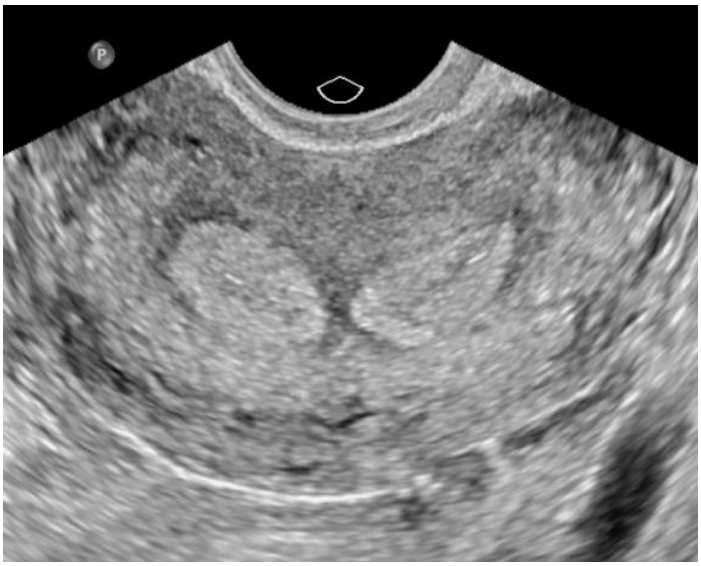

Figure: 3 A- Gray scale images of septate uterus

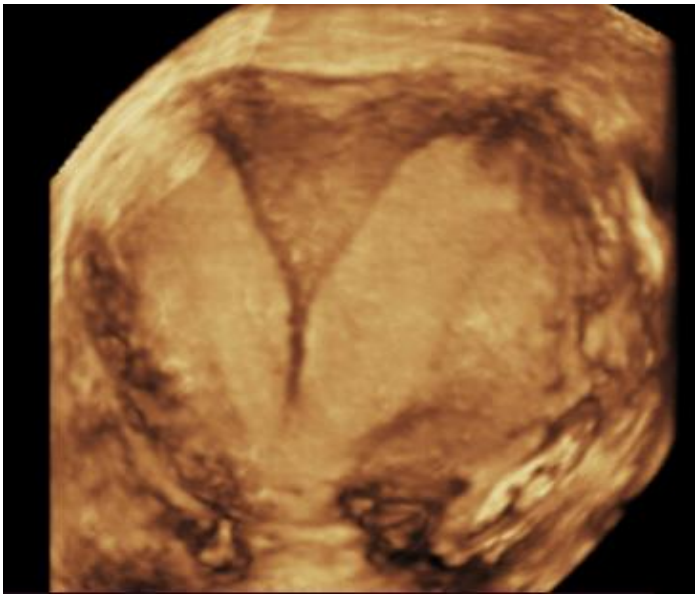

Figure: 3 B- Surface-rendered image of septated uterus.

## CONCLUSION

Twenty-seven years after the first introduction of 3D ultrasound into the clinical field of obstetrics and gynecology, 3D/4D sonography has experienced a wide spreading around the world. The easy handling of the ultrasound equipment, the variety of display modes after volume acquisition, the possibilities of volume manipulation and the advantage of storing volume data without any loss of quality provide the operator with an exceptional flexibility in daily routine examination. This is not only true in obstetrics but also in gynecology. However, 3D/4D ultrasound in obstetrics has the advantage that the fetus is

surrounded by amniotic fluid and that the demonstration of the outer surface of the fetus provides us with phenomenal images that are comparable to the pictures known from the textbook of embryology.

Future 3D/4D developments will be dependent from the progress in computer and transducer technology.

## REFERENCES


1. Merz E, Abramowicz JS. 3D/4D ultrasound in prenatal diagnosis: is it time for routine use? Clin Obstet Gynecol 2012Mar;55(1):336-351.
2. Benacerraf BR, Benson CB, Abuhamad AZ, Copel JA, A bramowicz JS, Devore GR, Doubilet PM, Lee W, Lev-Toaff AS, Merz E, et al. Three- and 4-dimensional ultrasound in obstetrics and gynecology: proceedings of the American Institute of Ultrasound in Medicine Consensus Conference. J Ultrasound Med 2005 Dec;24(12):1587-1597.
3. Merz E. Surface reconstruction of a fetus (28+2 GW) using HD live technology. Ultraschall Med 2012 Jun;33(3):211-212.
4. Benoit B. Three-dimensional surface mode for demonstration of normal fetal anatomy in the second and third trimesters. In: Merz E, editors. 3-D ultrasound in obstetrics and gynecology. Philadelphia, New York, Baltimore: Lippincott, Williams and Wilkins; 1998. p 95-100.
5. Chung, BL, Kim HJ, Lee KH. The application of threedimensional ultrasound to nuchal translucency measurement in early pregnancy (10-14 weeks): a preliminary study. Ultrasound Obstet Gynecol 2000 Feb;15(2):122-125.
6. Welter C, Merz E. Nuchal translucency-screening using 2D and 3D ultrasound. Ultrasound Obstet Gynecol 2003 Sep;22(Suppl1):13.
7. Lee W, McNie B, Chaiworapongsa T, Conoscenti G, Kalache KD, Vettraino IM, Romero R, Comstock CH. Three-dimensional ultrasonographic presentation of micrognathia. J Ultrasound Med 2002 Jul;21(7):775-781.
8. Pashaj S, Merz E, Wellek S. Biometric measurements of the fetal corpus callosum by three-dimensional ultrasound. Ultrasound Obstet Gynecol 2013 May 6. [Epub ahead of print].
9. Timor-Tritsch IE, Monteagudo A, Mayberry P. Threedimensional ultrasound evaluation of the fetal brain: the three horn view. Ultrasound Obstet Gynecol 2000 Sep;16(4):302-306.
10. Mangione R, Lacombre D, Carles D, Guyon F, Saura R, Horovitz J. Craniofacial dysmorphology and three-dimensional ultrasound: a prospective study on practicability for prenatal diagnosis. Prenat Diagn 2003 Oct;23(10):810-818.
11. Yanagihara T, Hata T. Three-dimensional sonographic visualization of fetal skeleton in the second trimester of pregnancy. Gynecol Obstet Invest 2000;49(1):12-16.
12. Krakow D, Williams J, Poehl M, Rimoin D, Platt L. Use of three-dimensional ultrasound imaging in the diagnosis of prenatal-onset skeletal dysplasias. Ultrasound Obstet Gynecol 2003 May;21(5):467-472.
13. Chaoui R, Heling KS. New developments in fetal heart scanning: three-and four-dimensional fetal echocardiography. Semin Fetal Neonatal Med 2005 Dec;10(6):567-577.
14. Gregg A, Steiner H, Staudach A, Weiner CP. Accuracy of 3D sonographic volume measurements. Am J Obstet Gynecol 1993;168:348.
15. Tabi S, Plavsic SK. The role of three-dimensional ultrasound in the assessment of congenital uterine anomalies. Donald School J Ultrasound in Obstet Gynecol 2012;6(4):415-423.
16. Benacerraf BR, Shipp TD, Bromley B. Three-dimensional ultrasound detection of abnormally located intrauterine contraceptive devices which are a source of pelvic pain and abnormal bleeding. Ultrasound Obstet Gynecol 2009 Jul;34(1): 110-115.
17. Makris N, Kalmantis K, Skartados N, Papadimitriou A, Mantzaris G, Antsaklis A. Three-dimensional hysterosonography versus hysteroscopy for the detection of intracavitary uterine abnormalities. Int J Gynaecol Obstet 2007 Apr:97(1): 6-9.